

## Endobronchial Paracoccidioidomycosis - Case Report

Pereira Junior RR<sup>1</sup>, Almeida CC<sup>2</sup>, Matos KCCM<sup>3</sup> and Bethlem EP<sup>4\*</sup>

<sup>1</sup>Master in Pneumology/Bronchoscopy, Federal State University of Rio de Janeiro (UNIRIO), Brazil

<sup>2</sup>Pneumology Resident in the University Hospital Gaffée-Guinle, Federal State University of Rio de Janeiro (UNIRIO), Brazil

<sup>3</sup>Master in Pneumology/Bronchoscopy Federal State University of Rio de Janeiro (UNIRIO), Brazil

<sup>4</sup>Emeritus Full Pneumology Professor, Federal State University of Rio de Janeiro (UNIRIO), Brazil

\***Corresponding authors:** Bethlem EP, Bronchoscopy Division from the University Hospital Gaffée-Guinle, Federal State University of Rio de Janeiro (UNIRIO). Rio de Janeiro, RJ, Brazil, Tel: 55 21 988302448, E-mail: epbethlem@uol.com.br

**Received Date:** June 25, 2021 **Accepted Date:** July 25, 2021 **Published Date:** July 27, 2021

**Citation:** Pereira Junior RR (2021) Endobronchial Paracoccidioidomycosis - Case Report. J Lung Dis Pulm Med 1: 1-4.

### Abstract

Paracoccidioidomycosis is a systemic disease caused by the dimorphic fungus *Paracoccidioides* genus: *P. brasiliensis* and *P. lutzii*. Although endemic to South and Central America, it can be found anywhere in the world. Its most frequent form of presentation is the chronic one after endogenous reactivation of a primary focus acquired in endemic areas. These focus almost always have a spontaneous resolution. It is a disease that presents a certain tropism for the lung and integument (skin and mucous tissue), with frequent involvement of the lungs, lymph nodes, oral cavity, pharynx and larynx. However, endobronchial involvement is rarely reported in the literature. A case of Paracoccidioidomycosis with direct observation evidence of endobronchial involvement is described. Paracoccidioidomycosis lesions often heal with tissue fibrosis, which may leave some important sequelae. The knowledge, disclosure and monitoring of this kind of injury is important for the better evolution of these patients.

**Keywords:** Endobronchial Mycosis; Paracoccidioidomycosis; Bronchoscopy; Fungal Diseases

## Introduction

Paracoccidioidomycosis (PCM) is a systemic disease caused by the dimorphic fungus *Paracoccidioides* genus (*P. brasiliensis* and *P. lutzii*) usually characterized by a granulomatous process of chronic evolution. Primary infection is normally self-limited in the immunocompetent host [1], usually with no symptomatology. A Chronic disease manifests itself by endogenous reactivation, only affecting the lungs or together with other organs, like the oral cavity, the pharynx, the larynx, the skin, adrenals, and the lymph nodes [1]. The view of endobronchial injury is rarely reported in the literature [2-4], unlike obstructive pulmonary functional impairment that is often related in this disease [5,6].

## Methodology

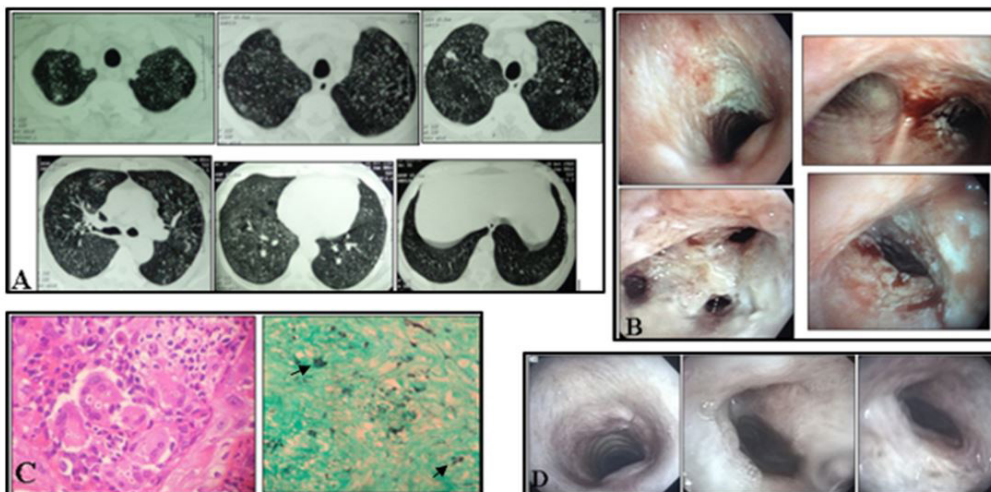
The authors describe the entire evolution of an adult male patient with Endobronchial Paracoccidioidomycosis from the diagnosis to the treatment evolution. They also comment some aspects of the literature and the importance of this presentation.

## Case Report

A fifty-three-year-old Brazilian rural working man presented cough with mucoid sputum, progressive dyspnea, weight loss (4kg), and low fever (37,3°C) in September, 2012. He was a heavy smoker (60 cigarettes a day for 30 years) with no comorbidities. Physical examination, blood count, and initial laborato-

rial biochemistry exploration were normal, except for a Reactive C protein (40mg/L – normal range less than 8mg/L) and ESR (50mm/h – normal range 0-15mm/h). Spirometry was normal. Mantoux, Human Immunodeficiency Virus (HIV) test, smear acid fast bacilli and direct fungal investigation were negative. The thorax high resolution computed tomography (HRCT) showed a predominant centrilobular nodular pattern with a scarce reticulation in the upper zones, some ground glasses in the middle zones, and one cavitated and other lobulated nodule in the right upper lobe (RUL - Figure 1-A). A Fiber optic bronchoscopy showed crusty white lesion with edema and mucosal irregularity in the subglottic region, right main bronchus (RMB), right upper lobe bronchus (RULB), and intermediate bronchus (IB), with reduction of their lumens (Figure 1-B). Bronchoalveolar lavage (BAL) was negative for acid fast bacilli, fungus and neoplastic cells. RMB lesion biopsy showed granulomatous infiltration with necrosis, Langhan's giant cells, and numerous fungus structures compatible with *Paracoccidioides brasiliensis* (Figure1-C). Serology was positive for PCM (immunodiffusion) and histoplasmosis (Elisa). BAL cultures were negative for *M. tuberculosis* and fungus.

He stopped smoking, and started on sulfamethoxazole/trimethoprim (160/80mg) for 3 months switching to itraconazole 200mg once a day for 6 months with a very good clinical improvement. New fiber optic bronchoscopy showed regression of the endo bronchial lesions, leaving some 25% reduction of the lumen specially in the RULB making impossible the passage of the fiber bronchoscope (Figure 1-D).



**Figure 1:** Images of HRCT (A), bronchoscopy (B and D) and histopathology (C)

A) HRCT showing a predominant centrilobular nodulation with a scarce reticulation in the upper zones, some ground glass in the middle zones, and one cavitated and other lobulated nodule in the RUL; B) Crusty white lesion with edema and mucosal irregularity in the subglottic region, RMB, RULB, and IB, with reduction of their lumens; C) RMB lesion biopsy (H&E and Grocott-Gomori) showing granulomatous infiltration with necrosis, Langham's giant cells and numerous fungus structures with a pilot wheel and Mickey mouse appearance (arrows); D) Regression of the endo bronchial lesions leaving some 25% reduction of the lumen specially in the RULB

## Discussion

Paracoccidioidomycosis is caused by a thermally dimorphic fungi of the genus *Paracoccidioides*. It is a systemic endemic mycotic disease with a geographic distribution limited to Central and South America, although it may occur in any part of the world. The most common form of the disease is the chronic one which represents reactivation of the primary infection only affecting the lungs or together with other organs.

Smoking increases the chance of PCM and it is often associated with the disease. Unlike other mycoses, PCM usually affects the immunocompetent host [6]. The clinical-epidemiological appearance of PCM can be bewildered with tuberculosis, and also in up to 20% of cases both diseases can coexist [7]. This was not observed in this patient, who presented a negative Mantoux test, a negative acid fast bacilli smear, and a negative tuberculosis culture.

In Brazil there is no exact data of incidence and prevalence of pulmonary mycoses [1,6]. All mycoses can affect several organs and systems, although the endobronchial involvement is not so frequently. The most common agents causing endobronchial involvement are *Aspergillus spp*, *Coccidioidis immitis*, agents of zigomycosis, *Candida spp*, *Cryptococcus neoformans*, and *Histoplasma capsulatum* [1]. Laryngeal lesions are frequent in PCM with difficult macroscopic differentiation from tuberculosis and neoplasm [1]. On the other hand, neoplasm and tuberculosis have usual endobronchial involvement differing from PCM that has rare records in the literature [2-4,8,9]. The bronchoscopy lesions visualized in this patient were striking and unusual, somewhat different from those found in endobronchial tuberculosis and neoplasias [9].

The clinic-epidemiological picture of the patient and the fungal morphological pilot wheel and Mickey mouse tissue aspect allowed the diagnosis of PCM [1,6,7] (Figure1C). The positive histoplasma serology represented a cross reaction widely known in literature<sup>10</sup>. The patient has stopped smoking since that time and nowadays he is completely asymptomatic. He initiated sulfamethoxazole, but after three months it was no more disposable in the free federal service, when he changed to itraconazole till complete nine months of treatment as recommended for mild to moderate Paracoccidioidomycosis [6].

The chronic granulomatous process generated by PCM can lead to fibrosis of the affected tissues, including the lung in about 50% of cases. A smaller percentage of cases evolves to

COPD and its implications [6,7]. As there is no active search for endobronchial injuries, the possibility of these injuries being the cause of the described sequels, can be raised. In addition, treatment-induced scar repair can lead to sequelae, the most common of which are pearly white atrophic scars, microtomy, laryngeal narrowing, chronic obstructive pulmonary disease and pulmonary fibrosis [1,6,7]. It is important to recognize the possibility of endobronchial involvement in PCM and its role in the prognosis of this illness, since it can contribute to healing injuries that determine bronchial strictures and severe impairment of the patient's quality of life and sometimes may need corrective intervention. Thus, a virtual bronchoscopy and even an invasive investigation of these patients should be considered for better management and monitoring.

This case is important to document one of the different possible externalizations of the PCM with relevance to the prognosis.

## References

1. Wanke B, Bethlem EP, Capone D, Lazzera M, Rego AJP, et al. (1995) Micosis pulmonares, In Pneumologia, edn 4. Edited by Bethlem N. São Paulo, SP: Atheneu; 1995: 449–77.
2. Klotzel K, Bueno AC, Queiroz R (1963) Involvement of the tracheobronchial tree in South American blastomycosis. *Dis Chest* 44: 368-73.
3. Santos JWA, Gazzoni MF, Neves KL, Dalcin TC, Mendes BC, et al. (2007) Endobronchial Paracoccidioidomycosis. *J Bronchol* 14: 193-5.
4. Sousa C, Alves J, Cordeiro M (2020) Paracoccidioidomycosis: Endobronchial Involvement in a Rare Disease in Europe. *Arch Bronconeumol*.
5. Costa AN, Benard G, Albuquerque AL, Fujita CL, Magri AS, et al. (2013) The lung in paracoccidioidomycosis: new insights into old problems. *Clinics (Sao Paulo)* 68: 441-448.
6. Mendes RN, Cavalcante RS, Marques SA, Marques MEA, Venturini J, et al. (2017) Paracoccidioidomycosis: Current Perspectives from Brazil. *The Open Microbiol J* 11: 224-82.
7. Queiros-Telles F, Escuissato DL (2011) Pulmonary Paracoccidioidomycosis. *Seminars in Respiratory and Critical Medicine* 32: 764-74.
8. Karnak D, Avery RK, Gildea TR, Sahoo D, Metha AC (2007) Endobronchial Fungal Disease: An Under-Recognized Entity. *Respiration* 74: 88-104.
9. Shahzad T, Irfan M (2016) Endobronchial tuberculosis – a review. *J Thorac Dis* 8: 3797-802.
10. Negroni R, De Flores CI, Robles AM (1976) Study of Serologic Cross Reactions Between the Antigens of Paracoccidioides Brasiliensis and Histoplasma Capsulatum. *Rev Asoc Argent Microbiol* 8: 68-73.

**Submit your manuscript to a JScholar journal and benefit from:**

- ¶ Convenient online submission
- ¶ Rigorous peer review
- ¶ Immediate publication on acceptance
- ¶ Open access: articles freely available online
- ¶ High visibility within the field
- ¶ Better discount for your subsequent articles

Submit your manuscript at  
<http://www.jscholaronline.org/submit-manuscript.php>