

Kylie Jenner Look- The Russian Lip Fillers

Anupriya Goel¹ and Apeksha Singh

Department of Dermatology at Sir Ganga Ram Hospital in New Delhi, India

Corresponding Author: Anupriya Goel, Department of Dermatology at Sir Ganga Ram Hospital in New Delhi, India, E-mail: anupriyabansal12@gmail.com

Received Date: March 07, 2025 **Accepted Date:** April 07, 2025 **Published Date:** April 10, 2025

Citation: Anupriya Goel, Apeksha Singh (2025) Kylie Jenner Look- The Russian Lip Fillers. J Dermatol Cosmet Ther 3: 1-5

Abstract

Background: Social media trends have become very popular in today's time and facial attractiveness plays a major role in the same. Fuller lips popularly known as Russian lips or Kylie Jenner's lips have become a viral trend, especially among young girls. Doing lip fillers is a special art where there is a thin line in giving a Kylie Jenner look vs giving a duck look appearance. Injecting dermatologists/aestheticians must have a thorough knowledge of the anatomy of the lips, the type of hyaluronic acid dermal filler being used for the procedure, and the technique of injection to give the desired result.

Aim: To assess the effectiveness of the new Russian lip filler technique with hyaluronic acid dermal fillers.

Method: A 24-year-old woman wanted fuller upper lips and improved vermilion body prominence. She underwent the Russian lip filler technique using 1ml of hyaluronic acid dermal filler. The treatment enhanced the definition of the vermilion body and increased lip volume.

Results: Hyaluronic acid dermal fillers are an effective technique in lip augmentation. Change in lip structure and shape significantly impacts the overall appearance of the face. The Russian lip technique enhances the show of the vermilion body which is a desired shape by many, especially after the boom of social media. This procedure brings immediate results and increases the confidence of an individual instantly. The results could last between 10-12 months.

Conclusion: The Russian lip technique is different in its procedure. It involves injecting dermal fillers in a retrograde linear thread, vertically. The injection is at a 45-degree angle directed medially. The technique focuses on increasing the vertical height of the lip and improving the vermilion show. This not only corrects thin lips but also enhances the lip shape and makes them look fuller. It is a non-surgical, minimally invasive, safe, and effective procedure that takes around 30-45 minutes to create the perfect shape of Russian lips.

Keywords: Russian Lip Technique; Hyaluronic Acid Dermal Fillers; Non-Surgical; Vermilion Show; Lip Augmentation

Introduction

Lips are one of the major factors for facial attractiveness. The procedure of facial rejuvenation especially lip augmentation has become increasingly popular in recent times. Lip fillers have been known for many years but the “Russian lip” filler technique is a relatively new trend. As the name says, this technique is supposed to have originated in Russia from the traditional stocking dolls- matryoshka and babushka [1]. In the Russian lip technique, the filler is injected vertically, starting at the vermillion border (not the white roll) of the lip, towards the pink roll. This technique focuses on achieving height and improving the show of vermillion body. Patients’ corrective needs vary from subtle enhancements to comprehensive recontouring [1], including vermillion border highlighting, correcting lip corners, and lifting the upper lip.

Although everyone has their own preferences, some people may prefer full, plump lips like those of Kylie Jenner and Russian lip filler is an effective technique for achieving this look.

Case Report

A 24-year-old female presented to our Berkowits Skin and Hair clinic who wanted correction of her thin up-

per lip. She wanted to enhance the show of her vermillion body, drawing inspiration from the full, plump lips of celebrity Kylie Jenner, while also wanting to preserve her natural look.

On examination, she had a thin upper lip, so we planned a treatment for her using the Russian lip technique. Written consent was taken before the procedure and for clicking “before and after” pictures. After taking consent, the Russian lip technique was planned using Hyaluronic acid dermal fillers.

Before the procedure, we cleaned the lips with an antibacterial solution and applied numbing cream on the lips for 30 minutes to prevent any potential discomfort. Then, the patient’s lips were injected with 1 ml of hyaluronic acid dermal filler using the Russian lip technique i.e the product is injected vertically in the vermillion body or just below the vermillion border at the angle of 45 degrees, starting at the root of the lip and working outward to the lip border. To ensure an even distribution of the fillers, we gently massaged the treated area after the lip filler infusion. Post operatively, an ice pack is applied to the lips to minimize swelling and inflammation. This technique transformed and reshaped her lip. It increased the vertical height of her thin lips and improved the vermillion show by giving lip fullness without making them look artificial or duck-like.

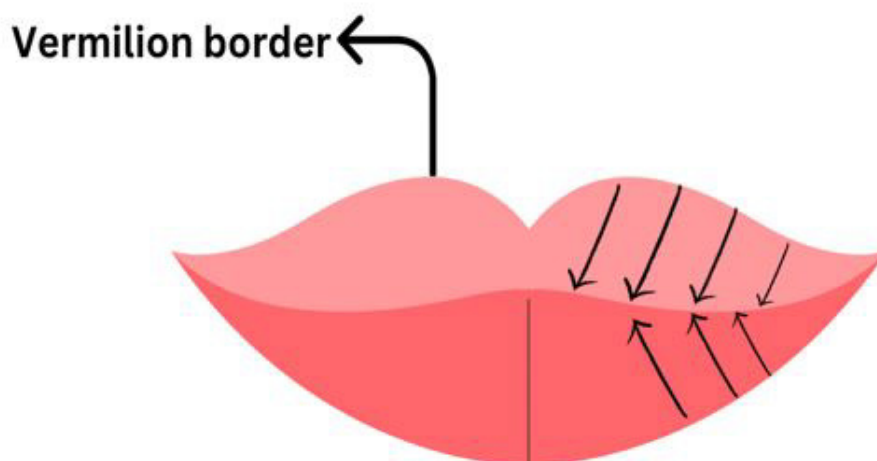


Figure 1: Marking & Technique for Russian lip filler

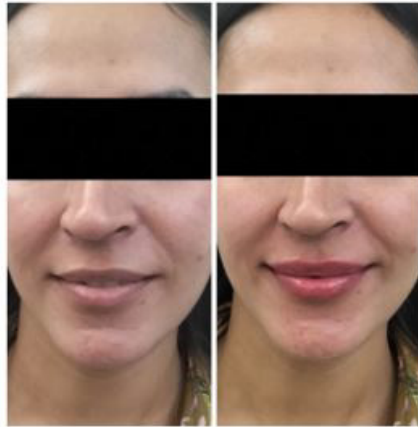
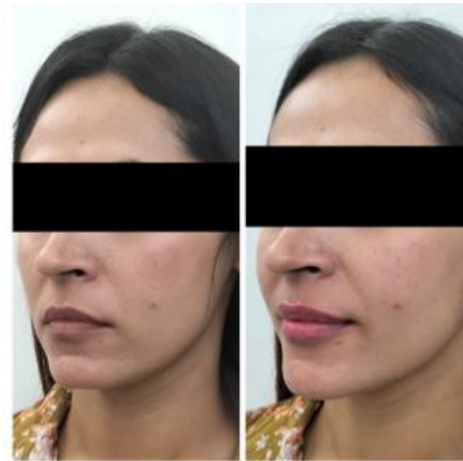
Figure 2: Before After



Before After

It is important to be careful while giving injections because

1. If it's given at 90 degrees instead of 45 degrees then the tapering of the lateral lip will get obliterated.
2. If greyish color appears while giving an injection, this indicates that the needle is too shallow, which can cause the Tyndall effect [2].
3. If the injection is given above the vermillion border that is from the white roll of the skin, then it can enhance the vermillion border unnaturally leading to Duck lips.

This technique needs a high level of expertise, experience, and understanding of the underlying anatomy.

The patient should be asked to avoid any anti-inflammatories or blood thinning medications for at least 3 days prior to the injection and strenuous exercise 2 hours prior to the procedure to minimize the potential adverse events that may occur [3].

The aftercare tips given to patients after the procedure are

1. Apply an ice cube covered in a thin cloth to minimize swelling, itching, bruising, and pain.
2. Stay hydrated and opt for foods that are easy to eat. Also, try to limit excessive sodium intake as it can worsen lip swelling.

3. Try to sleep with your head elevated on pillows for at least 24 hours to reduce swelling and avoid sleeping on your face.

4. Avoid strenuous exercise for 24 to 48 hours after getting lip fillers as it can elevate blood pressure and worsen swelling and bruising.

5. Avoid high temperatures like hot saunas, gyms, heated rooms, and direct sunlight for at least 48 hours after the procedure.

6. Do not apply any makeup for at least 24 to 48 hours after the treatment.

7. Avoid rubbing your lips for 24 hours after the procedure.

Then the patient is called for follow-up at 4 and 12 weeks following the filler injection.

Discussion

Lip fillers have a significant impact on the facial aesthetic industry, where several techniques have been proposed for lip beautification in terms of both the results and delivering a safe injection procedure. One of the techniques being most popular these days is the 'Russian lip technique' using Hyaluronic acid dermal fillers. Hyaluronic acid is a naturally occurring substance in the body that has the ability to attract water and induce swelling, increasing tissue volume and skin structural integrity. As a signalling molecule interacting with proteins, Hyaluronic acid causes several op-

posing effects based on molecular weight: pro-or anti-inflammatory effects, promotion or inhibition of cell migration, and activating or inhibiting cell division [4,5]. Using Hyaluronic acid filler to enhance lip volume is one of the most requested procedures in daily facial aesthetic practices [6,7].

Russian lip technique is considered different from the lip augmentation technique in the following ways

Technique- In the Russian lip technique, the filler is injected vertically starting at the vermilion body of the lip and drawing the filler outward towards the lip border.

Volume- Russian lip technique tends to lift the lip rather than adding excessive volume seeking a natural finish, that is it aims to improve the show of the vermilion body and make the lips higher and wider rather than plumping the lips in traditional lip filler.

Cost- The cost of the Russian lip technique and traditional lip augmentation with filler is approximately the same and the amount of filler required is usually similar.

Time- The time duration of both procedures is same, usually between 30 and 45 minutes.

After doing both procedures, one should anticipate swelling or bruising for 2-3 days.

Conclusion

The Russian lip technique is the newest, modified, and most on-trend technique that works to shape the lips into a subtle, aesthetically pleasing shape by accentuating the vermilion body.

The techniques and results for both the traditional one and the Russian filler are different. Russian filler can be used for the correction of thin lips which gives a lot of satisfaction to people and it can also be used for the enhancement of normal lips - giving them a Kylie Jenner look which makes them part of the trend. This technique is here to stay because it plays a major role in the correction and enhancement of the vermilion body. The procedure is minimally invasive, safe, effective, and convenient without any complications.

References

1. Zaky OB (2021) Russian Lips: The New and Trending Lip Filler Technique. Medical Solutions Barcelona.
2. Hirsch RJ, Narurkar V, Carruthers J (2006) Management of injected hyaluronic acid induced Tyndall effects. *Lasers Surg Med.* 38: 202-4.
3. Tracey A. Hotta, BScN, RN, CPSN, CANS, LNC (2018) Lip Enhancement: Physical Assessment, Injection Techniques, and Potential Adverse Events. *Plast Surg Nurs.* 38: 7-16.
4. Fallacara A, Baldini E, Manfredini S, Vertuani S (2018) Hyaluronic Acid in the Third Millennium. *Polymers (Basel).* 10: pii: polym10070701.
5. Cyphert JM, Trempus CS, Garantziotis S (2015) Size matters: Molecular weight specificity of hyaluronan effects in cell biology. *Int. J. Cell Biol.* 2015: 563818.
6. Nikolis A, Bertucci V, Solish N, et al. (2021) An objective, quantitative assessment of flexible hyaluronic acid fillers in lip and perioral enhancement. *Dermatol Surg.* 47: e168-73.
7. Votto SS, Read-Fuller A, Reddy L (2021) Lip augmentation. *Oral Maxillofac Surg Clin North Am.* 33: 185-95.

Submit your manuscript to a JScholar journal and benefit from:

- ☞ Convenient online submission
- ☞ Rigorous peer review
- ☞ Immediate publication on acceptance
- ☞ Open access: articles freely available online
- ☞ High visibility within the field
- ☞ Better discount for your subsequent articles

Submit your manuscript at
<http://www.jscholaronline.org/submit-manuscript.php>